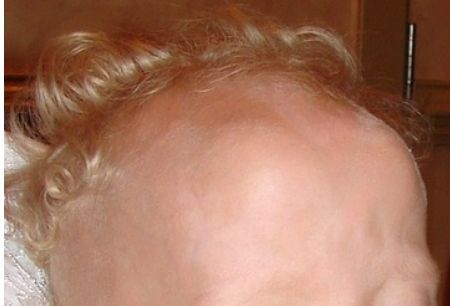

Features of Pallister-Killian Syndrome

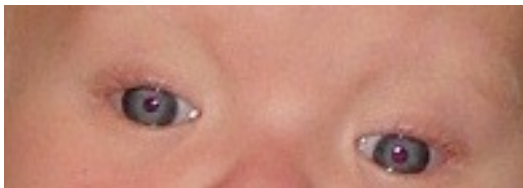Bi-temporal alopecia on a PKS child



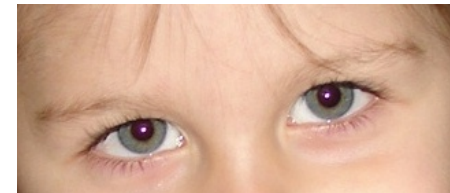Hair pattern in a typical child



Hypertelorism and broad nasal bridge, sparse eyebrows in a PKS child

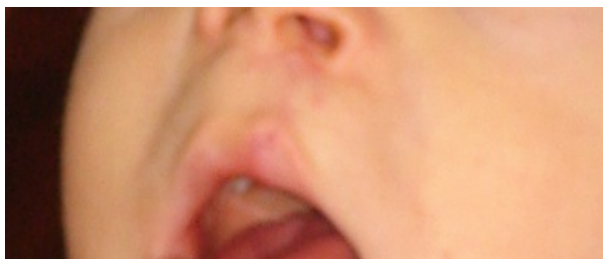


Typical eyes and nasal bridge, fuller eyebrows

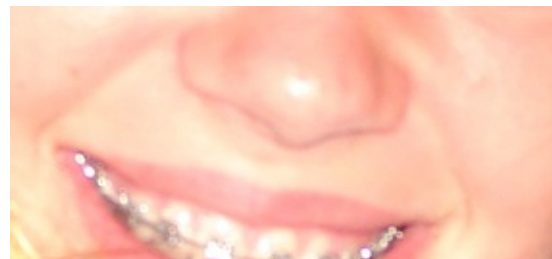


Features of Pallister-Killian Syndrome

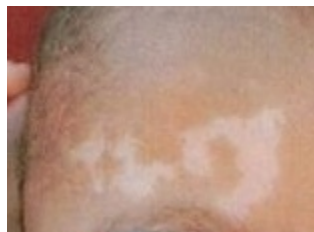Philtrum extending past the vermillion border



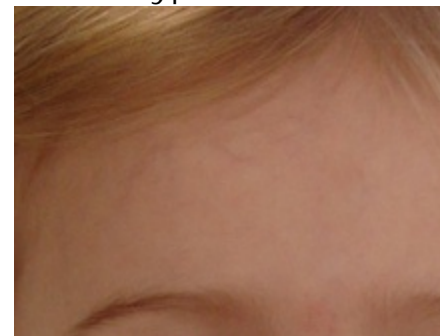Typical philtrum



Pigmentary dysplasia

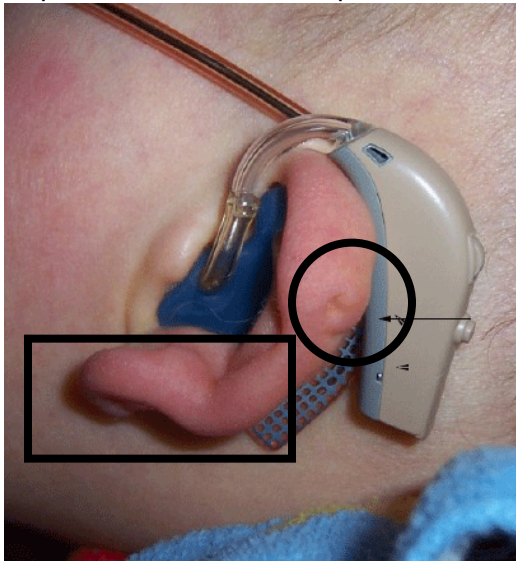


Typical skin

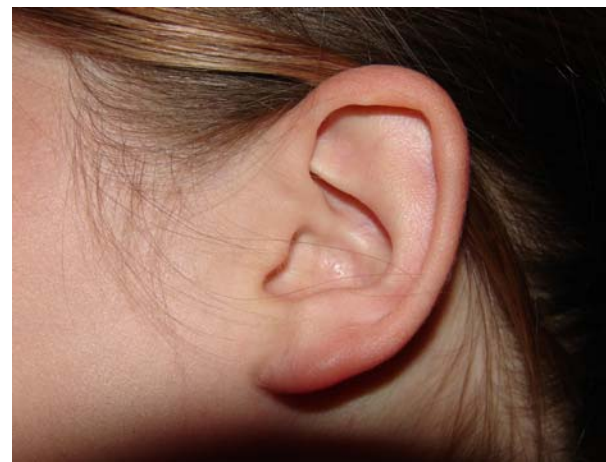

Features of Pallister-Killian Syndrome

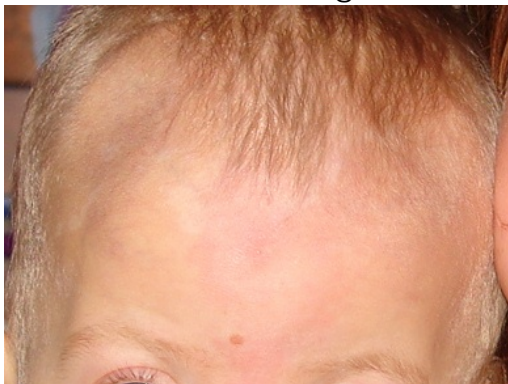Dysmorphic Ear and ear pits in a PKS child



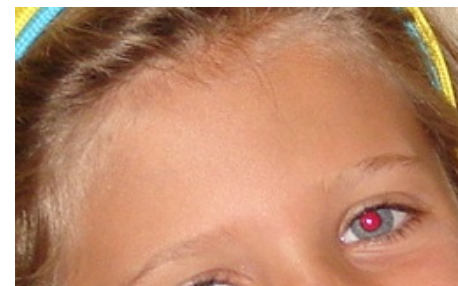Typical Ear



Frontal Bossing in a PKS child



Typical Forehead



Features of Pallister-Killian Syndrome

Other characteristics of PKS can include:

- GERD
- Congenital Diaphragmatic Hernia (CDH)
- 5 or more finger whorls
- Seizures
- Hypotonia
- High arched palate
- Mental retardation
- Hearing loss
- Accessory nipples

Please see www.pkskids.net for more information.